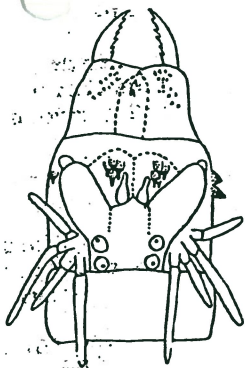


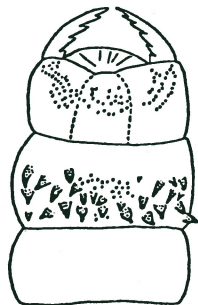
Nereis mediator

common in Bay

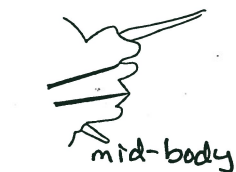

dorsum

proboscis



ventrum




mid-body



posterior (last 10 segments)

parapodium

bristles along inner margin more anterior segments



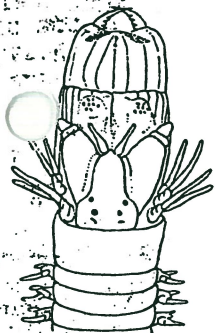notopodial falciger



spiniger

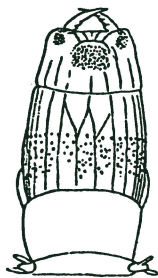
setae

Nereis vexillosa



dorsum

proboscis



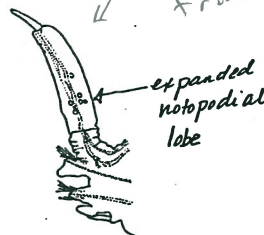
ventrum

Contracted notopodial lobe



posterior notopodium

parapodium



expanded notopodial lobe

Juv. small triangular lobe (as in the Nereids)

notopodial falciger

spiniger

setae

Platynereis bicanaliculata



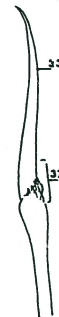whitish live - dark or whitish preserved

parapodium \*note pigmentation

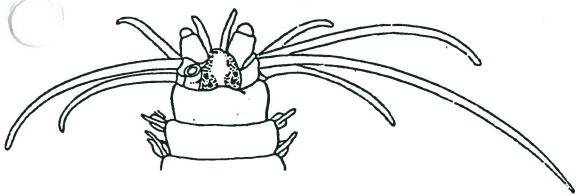


notopodial falciger

up thru anterior 10th!



spiniger



notopodial falciger